



**A NEW METHOD FOR DIAGNOSIS AND THERAPY
OF FIBROMYALGIA SYNDROME (FMS)**

**Surgical procedure as a cure
for intractable fibromyalgia syndrome of long duration**

Johann A. Bauer, Dr. Dr.
associate Professor for surgery
at the Ludwig-Maximilians-University of Munich

SPON. Johann A. Bauer

Myopain'04, Munich, July 18. - 22., 2004

The diagnostic problem:

Solved ✓

FMS pain begins in the switchboxes on the forearms and the inside of the ankles, follows the meridians and spreads as »algie diffusante« starting from the nerve endings in the acupuncture points. The diagnosis is established as soon as from all the examined acupuncture points the following are painful on pressure (pressure intensity is irrelevant in this context, and this even applies to the intensity of the tenderness on pressure or the pain reaction! It's the pattern of the painful points that matters here.)

Upper quadrant (fig.1-4)

Large intestine 4,6,7,8,9,10,11,13

Lung meridian 10,6,5,2,1

Gallbladder m. optional

Lower quadrant (fig 5-6)

Kidney 2 - 9

Spleen meridian 6

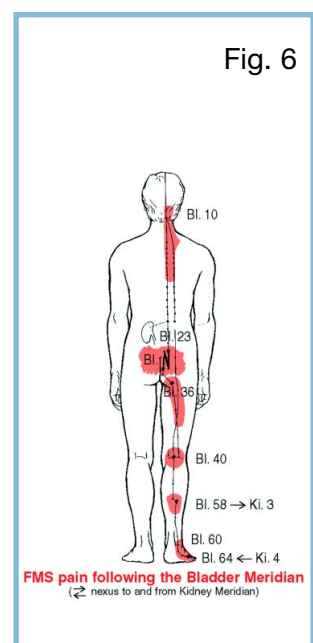
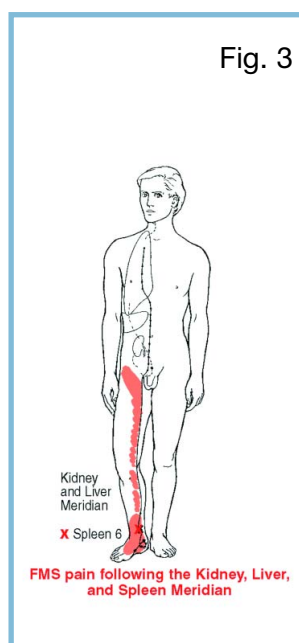
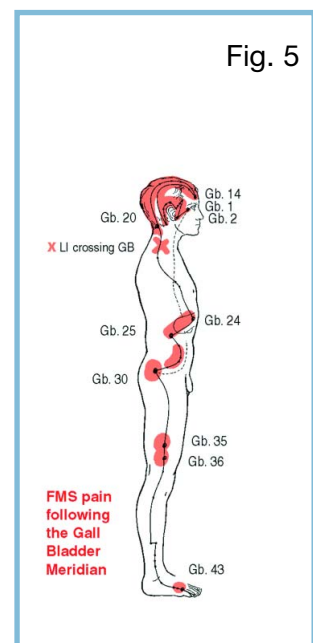
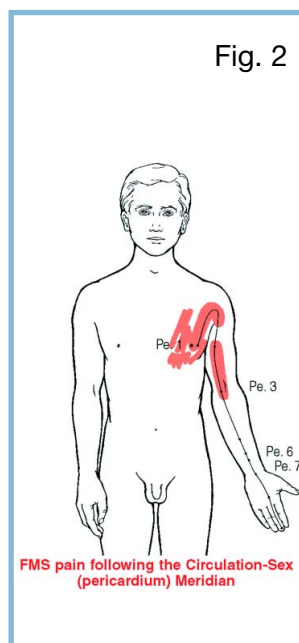
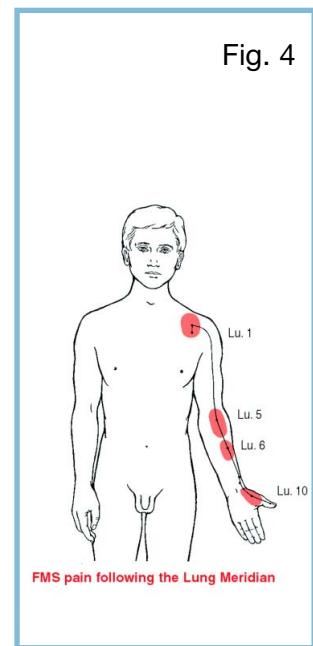
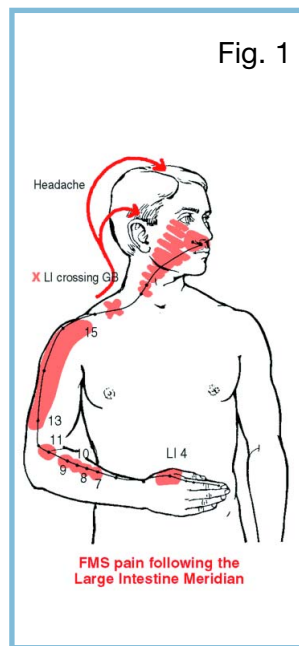
Bladder m. optional

Gallbladder m. optional

The accuracy of the diagnosis is excellent, the two key questions can be answered conclusively and beyond any doubt in the course of one hour:

- Does the patient suffer of FMS yes/no?
- Does a quadrant intervention make any sense yes/no?

There have been 5 wrong negative examinations due to dissimulation since 1990. There have been no wrong positive diagnoses: Among the persons who had surgery, plaque-like scar tissue was found with every single patient during surgery.



The therapeutic problem:

Solved ✓

One incision allows for the examination of 7-8 structures corresponding to the acupuncture points, for the removal of the protein-containing coatings and the decompression of the nerve segments and nerve endings laying below.

Upper quadrant:

S-shaped incision on the proximal back of the forearm (fig.7)

Lower quadrant:

L-shaped incision behind the inner ankle (fig.8)

Anaesthesia:

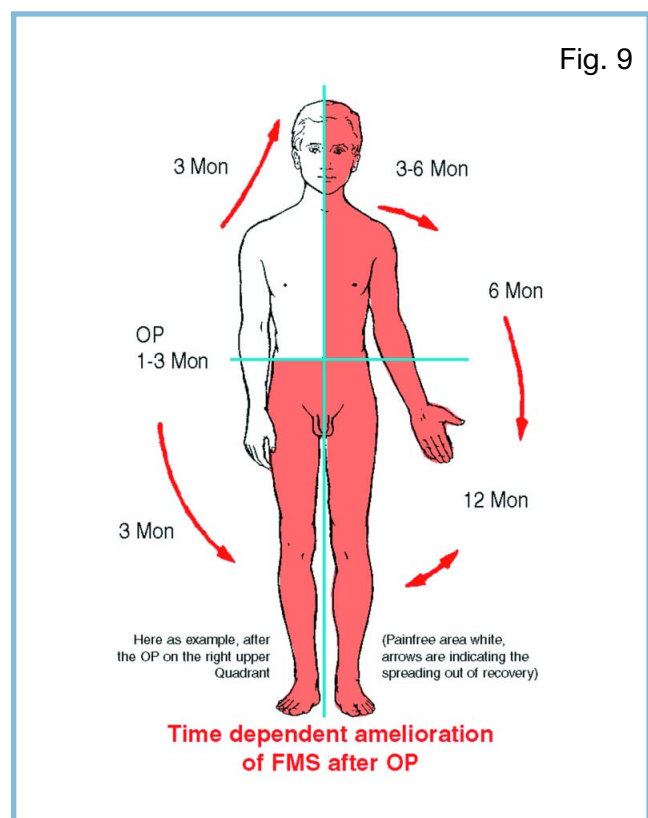
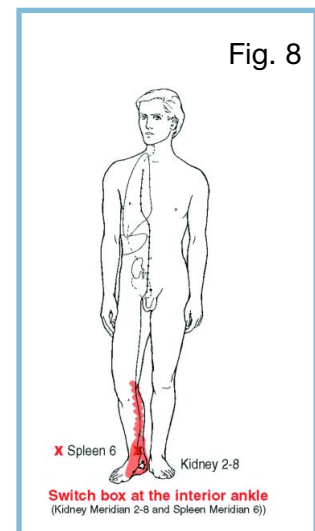
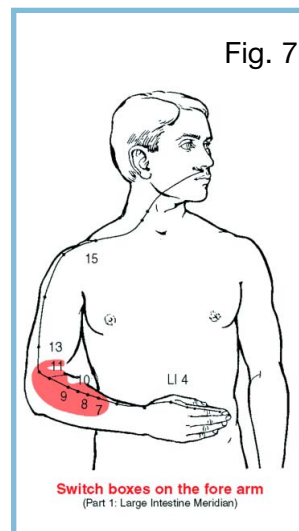
Regional/local anaesthesia

Purpose and meaning of this surgery and of the surgical therapy of carpal tunnel syndrome are the same. In the case of a carpal tunnel syndrome, surgery is considered the only causal therapy as well. The carpal tunnel syndrome also does not always restrict to one side of the body, it can affect both hands. In such case, a second operation must be performed on the opposite side and it would be false to assume that the first surgery was pointless now that the opposite side must be operated on.

In case of a quadrant intervention for FMS, one surgery can be sufficient. The cases requiring operations on all four quadrants are, however, rare.

Note:

At the present time, 80-90 patients are having surgery per month.



The clotting of the affected passage of the anatomical triad of artery - vein - nerve leads to an obstruction of the conduction of the small nerves that varies in intensity. This obstruction is noted as a nociceptive stimulus and represented as pain. The deafferentation leads to the relief of the over-strained pain threshold (which is not reduced, but rather over-stimulated). It is taking up its function again. Pain memory is running down - as it is not longer supplied any pathological afferences - like a wind-up clock.

